


CPD

Skin manifestations of COVID-19 in children: Part 2

D. Andina,¹ A. Belloni-Fortina,² C. Bodemer,³ E. Bonifazi,⁴ A. Chiriac,⁵ I. Colmenero,⁶ A. Diociaiuti,⁷ M. El-Hachem,⁷ L. Fertitta,³ D. van Gysel,⁸ A. Hernández-Martín,¹ T. Hubiche,⁹ C. Luca,⁵ L. Martos-Cabrera,¹ A. Maruani,¹⁰ F. Mazzotta,⁴ A. D. Akkaya,¹¹ M. Casals,¹² J. Ferrando,¹³ R. Grimalt,¹⁴ I. Grozdev,¹⁵ V. Kinsler,¹⁶ M. A. Morren,¹⁷ M. Munisami,¹⁸ A. Nanda,¹⁹ M. P. Novoa,²⁰ H. Ott,²¹ S. Pasmans,²² C. Salavastru,²³ V. Zawar,²⁴ A. Torrelo¹  and The ESPD Group for the Skin Manifestations of COVID-19

¹Department of Dermatology, Hospital Infantil Universitario Niño Jesús, Madrid, Spain; ²Pediatric Dermatology Unit, Department of Medicine DIMED, University of Padua, Padua, Italy; ³Department of Dermatology, Hospital Necker Enfants Malades, Paris Centre University, Paris, France; ⁴Dermatologia Pediatrica Association, Bari, Italy; ⁵Nicolina Medical Center, Iasi, Romania; ⁶Department of Pathology, Hospital Infantil Universitario Niño Jesús, Madrid, Spain; ⁷Dermatology Unit, Bambino Gesù Children's Hospital, IRCCS, Rome, Italy; ⁸Department of Pediatrics, O. L. Vrouw Hospital, Aalst, Belgium; ⁹Department of Dermatology, Université Côte d'Azur, Nice, France; ¹⁰Department of Dermatology, Unit of Pediatric Dermatology, University of Tours, SPHERE-INISERM1246, CHRU Tours, Tours, France; ¹¹Department of Dermatology, Ulus Liv Hospital, Istanbul, Turkey; ¹²Department of Dermatology, Hospital Universitari de Sabadell, Barcelona, Spain; ¹³Department of Dermatology, Hospital Clinic, Barcelona, Spain; ¹⁴Faculty of Medicine and Health Sciences, Universitat Internacional de Catalunya, Barcelona, Spain; ¹⁵Department of Dermatology, Children's University Hospital Queen Fabiola, Brussels, Belgium; ¹⁶Department of Paediatric Dermatology, Great Ormond Street Hospital for Children, NHS Foundation Trust, London, UK; ¹⁷Pediatric Dermatology Unit, Department of Pediatrics and Dermato-Venereology, University Hospital Lausanne and University of Lausanne, Lausanne, Switzerland; ¹⁸Department of Dermatology and Sexually Transmitted Diseases, Jawaharlal Institute of Postgraduate Medical Education and Research (JIPMER), Puducherry, India; ¹⁹As'ad Al-Hamad Dermatology Center, Kuwait City, Kuwait; ²⁰Department of Dermatology, Hospital San Jose, Bogota, Colombia; ²¹Division of Pediatric Dermatology, Children's Hospital Auf der Bult, Hannover, Germany; ²²Erasmus MC University Medical Center Rotterdam, Sophia Children's Hospital, Rotterdam, The Netherlands; ²³Department of Paediatric Dermatology, Colentina Clinical Hospital, Carol Davila University of Medicine and Pharmacy, Bucharest, Romania; and ²⁴Department of Dermatology, Dr Vasant Rao Pawar Medical College, Nashik, India

doi:10.1111/ced.14482

Summary

The current COVID-19 pandemic is caused by the SARS-CoV-2 coronavirus. The initial recognized symptoms were respiratory, sometimes culminating in severe respiratory distress requiring ventilation, and causing death in a percentage of those infected. As time has passed, other symptoms have been recognized. The initial reports of cutaneous manifestations were from Italian dermatologists, probably because Italy was the first European country to be heavily affected by the pandemic. The overall clinical presentation, course and outcome of SARS-CoV-2 infection in children differ from those in adults, as do the cutaneous manifestations of childhood. In this review, we summarize the current knowledge on the cutaneous manifestations of COVID-19 in children after thorough and critical review of articles published in the literature and from the personal experience of a large panel of paediatric dermatologists in Europe. In Part 1, we discussed one of the first and most widespread cutaneous manifestations of COVID-19, chilblain-like lesions. In this part of the review, we describe other manifestations, including erythema multiforme, urticaria and Kawasaki disease-like inflammatory multisystemic syndrome. In Part 3, we discuss the histological findings of COVID-19 manifestations, and the testing and management of infected children for both COVID-19 and any other pre-existing conditions.

Correspondence: Dr Antonio Torrelo, Department of Dermatology, Hospital Niño Jesús, Menendez Pelayo 65, Madrid 28034, Spain
E-mail: atorrelo@aedv.es

Conflict of interest: the authors declare that they have no conflicts of interest.

Correction added on 16 January 2021, after first online publication: one of the author names and affiliations have been updated.

Accepted for publication 13 August 2020

Introduction

The current COVID-19 pandemic has affected almost all countries worldwide. The overall clinical presentation, course and outcome of SARS-CoV-2 infection, as well as the cutaneous manifestations of childhood COVID-19 differ from those of adults. Certain manifestations are more frequently seen in children and young patients. Below we describe some of the other manifestations of COVID-19, including erythema multiforme (EM), urticaria and Kawasaki disease (KD)-like inflammatory multisystemic syndrome.

Erythema multiforme

EM is an acute, self-limiting hypersensitivity condition, which is characterized clinically by a distinctive skin eruption with symmetrical erythematous lesions called iris or target lesions.^{1,2}

The most common cause of EM is systemic infection (up to 90%), while drug-associated EM is reported in < 10% of cases.³ In children, the two pathogens most frequently involved in EM are herpes simplex virus (HSV) and *Mycoplasma pneumoniae*.⁴

An EM-like eruption has been observed in association with SARS-CoV-2 infection, both in adults and in children^{5,6} (Fig. 1). In one report⁷ a 17-year-old patient presented with discrete acral papules and targetoid lesions. In another report, four children (three boys and one girl) with chilblain-like lesions also had associated EM, with both true target lesions and targetoid lesions; one of these patients had a positive PCR result for SARS-CoV-2, and skin biopsies carried out in two of the cases demonstrated endothelial positive immunohistochemistry stain to SARS-CoV-2 spike protein.⁸ A 6-year-old boy with acral target lesions of EM and severe, painful cheilitis and conjunctivitis had a positive COVID-19 PCR result.⁹ Other cases of EM-like lesions on the heels of both feet in children can be better regarded as chilblains with central purpuric lesions and peripheral erythema.¹⁰

Children with EM in the setting of COVID-19 have been otherwise asymptomatic or have had only mild respiratory or gastrointestinal symptoms.⁸

Urticaria

Urticaria presents with usually pruritic, circumscribed, raised weals, which characteristically last < 24 h. The most common causes of urticaria are allergens, food pseudoallergens, insect envenomation, drugs and infections. Viruses are a common cause of urticaria in

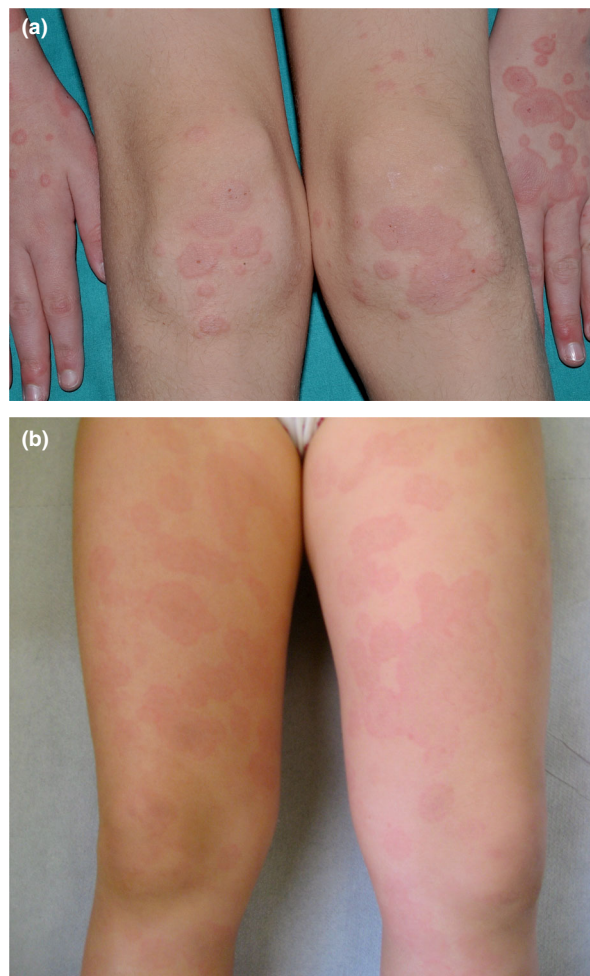


Figure 1 (a,b) Typical target and targetoid lesions in COVID-19-related erythema multiforme.

children,¹¹ including parvovirus, rhinovirus, rotavirus, Epstein–Barr virus (EBV), hepatitis A, B and C viruses, and human immunodeficiency virus, among others. Bacterial infections (urinary tract infections, *Streptococcus*, *Mycoplasma*, *Helicobacter pylori*) and some parasites can also be associated with urticaria.

Urticaria represents about 10%–20% of the cutaneous manifestations in patients with COVID-19^{5,12–24} (Fig. 2). Most reported cases of urticaria in COVID-19 were adults, and in our experience, children with urticaria and COVID-19 appear mostly asymptomatic apart from the urticarial rash. Additionally, most of the patients were not tested, but had household contact with confirmed or suspected patients with COVID-19. Only a minority of patients were biopsied, all of them adults.^{13,14}

Viral infections may cause nonimmunological urticaria by mast cell activation via complement or vasculitis as COVID-19 virus binds angiotensin-converting enzyme (ACE)2 receptors on blood vessels. Antibodies may therefore deposit at vascular walls with ensuing immune reaction. Urticaria might be associated with bradykinin in the kinin–kallikrein system in conjunction with ACE2.¹⁵

Vesicular exanthem

There is no consensus regarding the definition of 'COVID-19 vesicular rash'.^{25–27} The vesicular exanthem was reported in 4% of 53 cases with dermatological symptoms and positive nasopharyngeal PCR for SARS-Cov-2 in a prospective multicentre study in China and Italy,²⁸ in 9% of confirmed or suspected COVID-19 cases with skin symptoms in Spain,⁵ and in 15% of suspected or confirmed cases in France.²⁶

Initially, the vesicular eruption reported in patients diagnosed with COVID-19 was a varicella-like papulovesicular rash.²⁸ This kind of rash may possibly be more frequent in middle-aged women,^{5,28} but it has also been reported in adult men and

children. Vesicular lesions are thought to appear in the early stages of COVID-19 disease, and occasionally even before the onset of other manifestations,^{5,29} compared with other skin manifestations occurring later.³⁰

The eruption is monomorphic²⁷ with disseminated vesicles, appearing after a median latency of 3 days after first respiratory symptoms (Fig. 3) and persisting for around 8 days with no correlation with severity of infection.^{28,31–33} Vesicles predominate on the trunk, but the limbs may also be affected³⁴ and papular, crusted³⁴ or haemorrhagic lesions³⁵ are also associated. Itch is common, but is usually mild.²⁸

Most authors advise using PCR on vesicle fluid to test for HSV-1 and HSV-3 (varicella zoster virus; VZV) to exclude HSV and VZV. The histology of these also differs from that of COVID-19 vesicular rash.^{24,34,36,37}

The pathogenesis of the vesicular exanthema is unknown and other viruses, such as HSV-1, HSV-2, human herpesvirus (HHV)-6 and HHV-7, VZV, parvovirus and EBV, have been simultaneously detected in some patients with COVID-19.^{5,32,38}

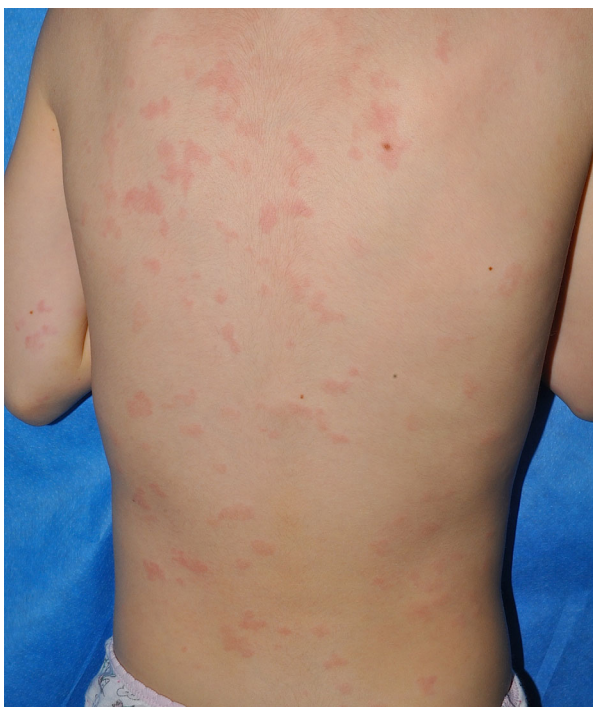

Figure 2 Urticaria in a child with COVID-19.

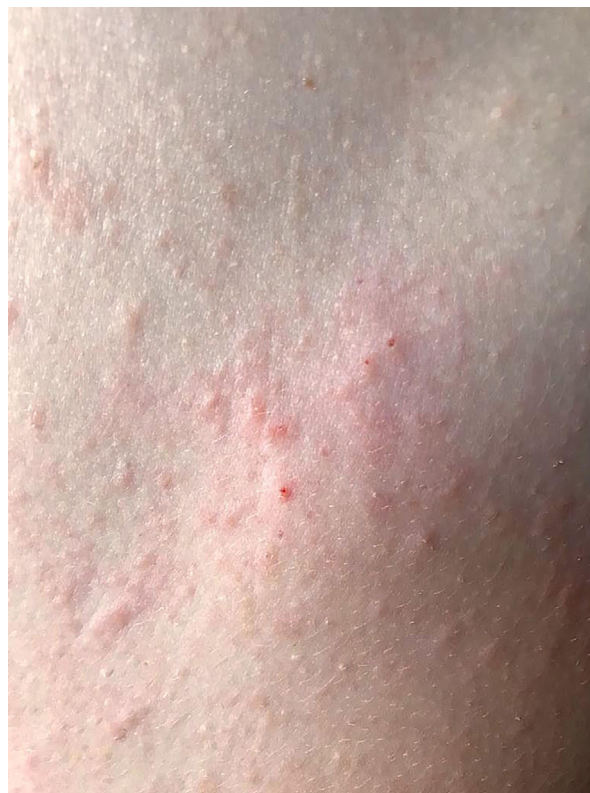

Figure 3 Vesicular exanthem of COVID-19.

Kawasaki disease-like inflammatory syndrome (paediatric inflammatory multisystem syndrome)

KD is the most common vasculitis in childhood³⁹ and its diagnosis is based on clinical and laboratory criteria.^{40,41} The role of a nonspecific infection, such as seasonal coronavirus, as a trigger factor is classically suggested.^{41–43}

Although COVID-19 affects children less severely than adults,⁴⁴ a temporospatial association between COVID-19 and a severe multisystemic condition has been observed in children in various countries.^{45–49} This has been named paediatric inflammatory multisystem syndrome (PIMS) temporally associated with SARS-CoV-2 infection in Europe⁵⁰ and multisystem inflammatory syndrome in children in the USA.⁵¹

Around 40 articles have been published, including case reports (USA and Italy),^{52,53} case series⁴⁵ and two cohort studies.⁴⁸

Demographics

The mean age of patients with PIMS is higher than that usually seen with classic KD, with age ranging from a mean \pm SD 7.5 ± 3 – 5 ⁴⁷ to a median of 7.9 (range 3.7–16.6 years).⁴⁸ In the French cohort,⁴⁸ the proportion of patients with at least one parent originating from sub-Saharan Africa or a Caribbean island was about 57%. This was also highlighted in patients with hyperinflammatory shock syndrome,⁴⁰ with a high frequency of African-American patients affected by more severe COVID-19 forms.^{54,55} In a French study, 14% of patients had at least one parent originating from Asia.⁴⁹

Although overweight is a well-known risk factor for complications of COVID-19,⁴⁴ overweight was not underlined as a risk factor in severe and fatal forms of COVID-19 in children.⁵⁶

Clinical features

According to the American Heart Association criteria of KD³³ a complete form of KD was found in 50%–52% of cases,^{47,48} and an incomplete form of the disease, according to the American Heart Association criteria⁵⁷ was seen in 48%–50% of cases.^{47,48} The diagnosis of incomplete types was based on fever for > 5 days plus two or three classic criteria, considering laboratory anomalies and/or abnormal echocardiography (coronary aneurysms, left ventricular depression, mitral valve regurgitation,

pericardial effusion) as associated additional diagnostic criteria.⁴⁷

Generally, however, in comparison with KD, children with PIMS display an over-representation of gastrointestinal (GI) symptoms, myocarditis and shock syndrome. GI symptoms were found in a large proportion of patients. Diarrhoea was present in 60% of an Italian cohort⁴⁷ and 100% of a French cohort,⁴⁸ hence the predominance of GI symptoms could lead to diagnostic and therapeutic delay as well as unnecessary surgical interventions.

Cardiovascular symptoms including hypotension or signs of hypoperfusion were present in 50%–57% of cases in two studies,^{47,48} and myocarditis in 76% of patients in the French series.⁴⁸ Hyperinflammatory shock, showing similar features to atypical KD (KD shock syndrome; KDSS) have been described recently⁴⁵ and was described in a French study.⁵⁸

KDSS is a rare syndrome, affecting 1.5%–7% of patients with KD, and is characterized by myocardial dysfunction associated with decreased peripheral vascular resistance, and a severe inflammatory syndrome with high levels of IgE, C-reactive protein (CRP) and procalcitonin.⁵⁸ A higher incidence has been found in western countries, i.e. Europe and America.⁵⁹

Skin and mucosal manifestations

Currently, the cutaneous manifestations at the moment appear to be nonspecific to the pathogenesis, being similar to those usually described in KD or in viral infections (Fig. 4).

Cutaneous and mucosal manifestations are common in PIMS.^{46–48} A nonexudative conjunctivitis was described in 50% of Italian patients with the complete form and 30% with the incomplete form,⁴⁷ and in 81% of French patients.⁴⁸ A 'polymorphic' rash was seen in 50% of Italian patients with the complete form and 30% with the incomplete form,⁴⁷ and in 76% and 20% of French patients with the complete and incomplete forms, respectively.⁴⁸ Perineal or face desquamation was observed in 19% of French patients.⁴⁸ Finally, hand and feet anomalies (erythema, firm induration or both) were described in 50% of Italian patients⁴⁷ and 48% of French patients.⁴⁸ The semiology of the cutaneous lesions had no apparent specificity.

Laboratory studies

Inflammatory markers, including CRP, erythrocyte sedimentation rate, neutrophil count and ferritin were

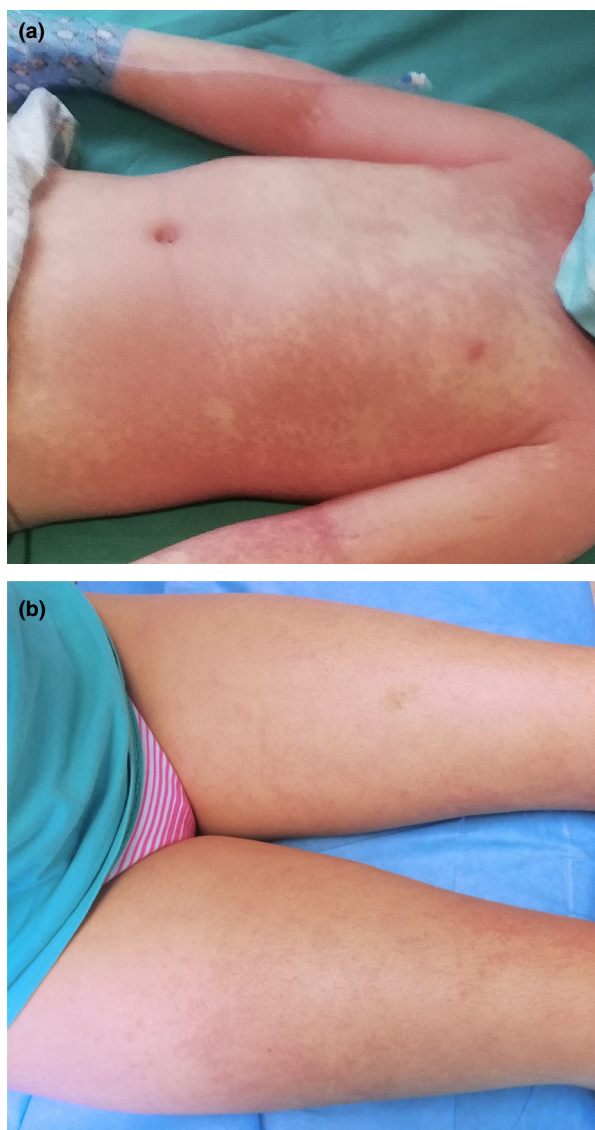


Figure 4 (a,b) Erythematous exanthem in paediatric inflammatory multisystem syndrome.

elevated in almost all cases, and pancytopenias have also been described along with other biochemical derangements.^{47,48} Median interleukin-6 level was shown to be elevated⁴⁸ and cytokine storm has been reported.^{49,60,61}

Echocardiography

In the Italian study,⁴⁷ 60% had abnormal heart ultrasonography results, including aneurysms (20%), decreased ejection fraction (50%), mitral valve regurgitation anomalies (40%) and pericardial effusion (40%).

In the French study,⁴⁸ 38% of patients had coronary artery abnormalities including dilatations and increased coronary visibility, but no coronary aneurysms.

Evidence of SARS-CoV-2 infection

The incidence of KD in 2020 has been much higher than expected and the number of severe cases of KD has been higher than at any time in the past 5 years.⁴⁷ Other members of the coronavirus family (such as HCoV-NH, very similar to HCoV-NL63) have previously been suspected to trigger or cause KD.^{41–43,62–64}

In children with KD-like multisystem inflammatory syndrome during the COVID-19 pandemic, reverse transcription-PCR was positive in only 20%–38% of patients,^{47,48} and IgG serology testing was positive in 80%–90%.^{47,48} There are of course caveats with serology testing.⁶⁵

Treatment

During the pandemic, > 80% of paediatric patients required admission to an intensive care unit⁴⁸ and received intravenous fluid resuscitation and/or vasoactive agents, plus systemic antibiotics.^{65,66} All patients received aspirin (low- or high-dose) at admission and discharge, and were also treated with high-dose intravenous immunoglobulin infusion 2 g/kg, while over half required adjunctive steroids (methylprednisolone 2 mg/kg/day).^{47,48}

Other manifestations

Several nonspecific viral exanthems have been putatively attributed to SARS-CoV-2. Vasculopathic rashes including purpuric thrombocytopenic purpura,⁶⁷ Dengue-like exanthem,^{68,69} acro-ischaemia⁷⁰ and live-doid eruptions^{5,71} have been linked to COVID-19 in adults and occasionally in children as well^{72,73} (Fig. 5). As in other viral exanthems, a tendency for flexural involvement has been reported.^{69,74} Histological findings range from thrombotic vasculopathy⁷⁵ to perivascular lymphocytic infiltrate with abundant red cell extravasation and dermal oedema without vascular occlusion,⁷⁶ pointing to a paucisymptomatic inflammatory peripheral vasculopathy as the basic pathogenic mechanism.

Maculopapular exanthems were reported in 47% of Spanish adult patients with skin manifestations (but 78% were on one or more drug)⁵ and in 14 out of 18 Italian cases⁷⁷ (Fig. 6).

Pathology findings (see Part 3 of this series) do not differ from those of other viral infections and drug

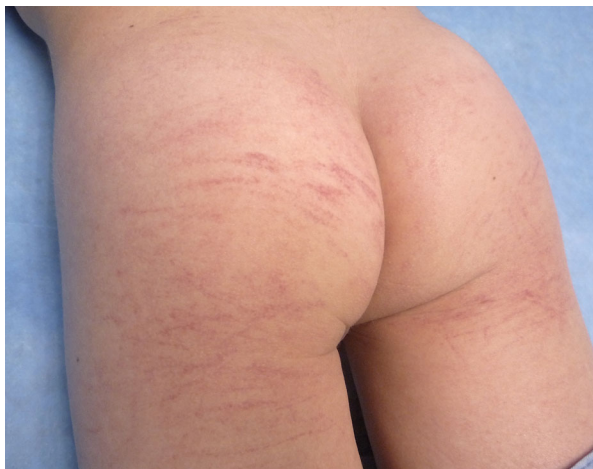

Figure 5 Purpuric rash in a child with suspected COVID-19.

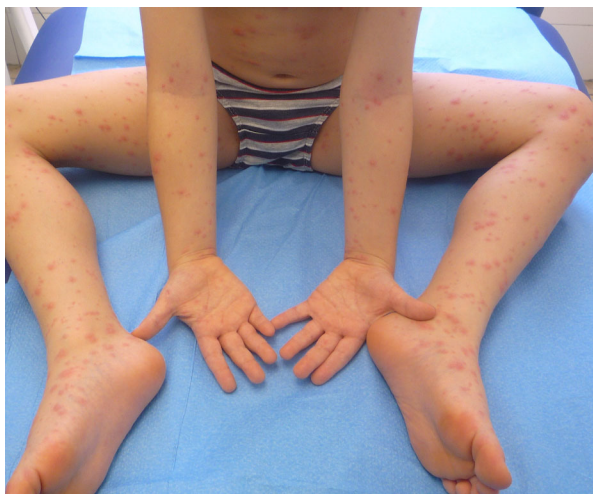

Figure 6 Maculopapular exanthem in COVID-19.

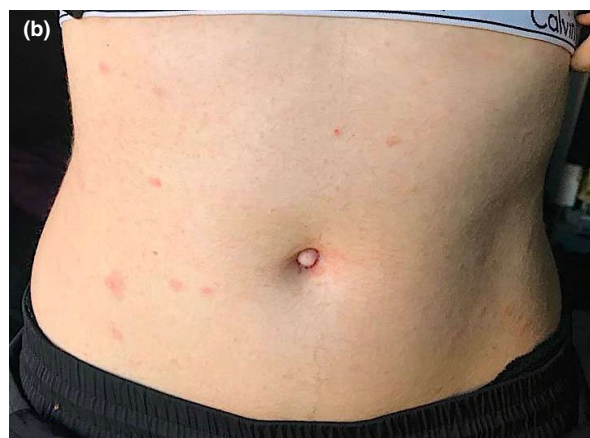
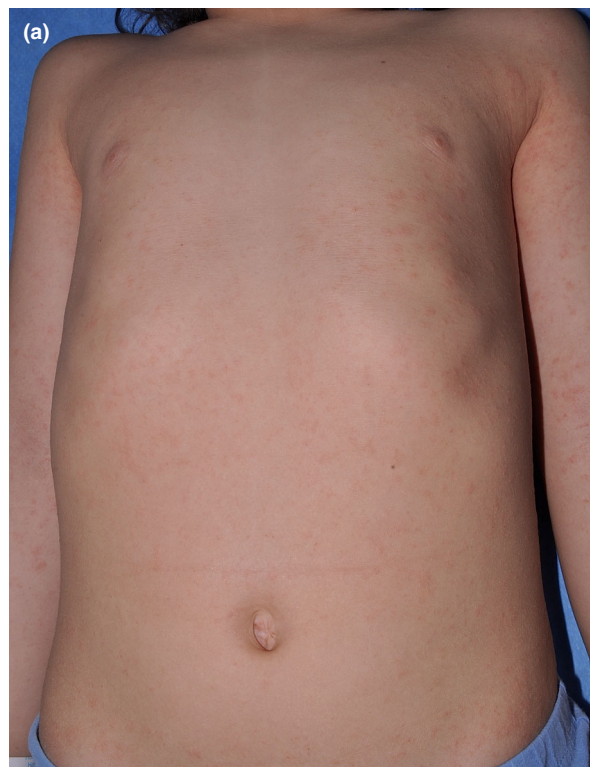
Figure 7 (a,b) Pityriasis rosea-like eruption in two children with suspected COVID-19.

eruptions.^{78,79} Despite thousands of patients with COVID-19 receiving therapy, available data on the prevalence of drug eruptions are lacking and only anecdotal reports suggesting such a possibility have been published to date.^{69,80} Similarly, pityriasis rosea-like eruptions have been widely reported,^{5,81} but whether this is a specific COVID-19 eruption or whether it is due to a reactivation of HHV-6⁸² is not known (Fig. 7).

Oral mucosa findings have received little attention in all age groups. In a recent study performed in a field hospital in Spain, up to 25% of patients showed oral mucosa abnormalities, 18% of which had

macroglossia and anterior papillitis.⁸³ A 12-year-old girl with tongue swelling and prominent papillae with positive COVID-19 PCR test has been reported,⁷² further supporting the potential involvement of the oral cavity in patients with COVID-19.

Some of these rashes may not be directly related to SARS-CoV-2,⁸⁴ and other aetiologies of cutaneous rashes should be kept in mind⁸⁵ even during the COVID-19 pandemic.

Learning points

- Lesions indistinguishable from EM may occur in association with chilblains in children suspected of COVID-19.
- Urticaria occurs in 10%–20% of patients with skin lesions in COVID-19, and its incidence may be underestimated in children.
- A monomorphic vesicular or papulovesicular, disseminated exanthema has been described both in patients with PCR-proven and those with suspected COVID-19, mostly in adults.
- PIMS is a rare, but most severe form of COVID-19 in children; it resembles severe KDSS and presents with skin lesions that may mimic KD.
- Other forms of exanthems, whose relation to COVID-19 is unknown, have been reported during the COVID-19 outbreak; these include purpuric rashes, maculopapular exanthems, pityriasis rosea-like eruptions and oral findings, among others.

References

- 1 Grünwald P, Mockenhaupt M, Panzer R, Emmert S. Erythema multiforme, Stevens-Johnson syndrome/toxic epidermal necrolysis – diagnosis and treatment. *J Dtsch Dermatol Ges* 2020; **18**: 547–53.
- 2 French LE, Prins C. Erythema multiforme, Stevens-Johnson syndrome and toxic epidermal necrolysis. In: *Dermatology*, 3rd edn (Bolognia JL, Jorizzo JL, Schaffer JV, ed). Atlanta: Elsevier Saunders, 2012: 319–33.
- 3 Siedner-Weintraub Y, Gross I, David A *et al*. Paediatric erythema multiforme: epidemiological, clinical and laboratory characteristics. *Acta Derm Venereol* 2017; **97**: 489–92.
- 4 Sokumbi O, Wetter DA. Clinical features, diagnosis, and treatment of erythema multiforme: a review for the practicing dermatologist. *Int J Dermatol* 2012; **51**: 889–902.
- 5 Galván Casas C, Català A, Carretero Hernández G *et al*. Classification of the cutaneous manifestations of COVID-19: a rapid prospective nationwide consensus study in Spain with 375 cases. *Br J Dermatol* 2020; **183**: 71–7.
- 6 Jimenez-Cauhe J, Ortega-Quijano D, Carretero-Barrio I *et al*. Erythema multiforme-like eruption in patients with COVID-19 infection: clinical and histological findings. *Clin Exp Dermatol* 2020; **45**: 892–5. <https://doi.org/10.1111/ced.14281>
- 7 Janah H, Zinebi A, Elbenaye J. Atypical erythema multiforme palmar plaques lesions due to SARS-CoV-2. *J Eur Acad Dermatol Venereol* 2020; **34**: e373–5.
- 8 Torrelo A, Andina D, Santonja C *et al*. Erythema multiforme-like lesions in children and COVID-19. *Pediatr Dermatol* 2020; **37**: 442–6.
- 9 Labé P, Ly A, Sin C *et al*. Erythema multiforme and Kawasaki disease associated with COVID-19 infection in children. *J Eur Acad Dermatol Venereol* 2020; **34**: e539–41. <https://doi.org/10.1111/jdv.16666>
- 10 García-Gil MF, García García M, Monte Serrano J *et al*. Acral purpuric lesions (erythema multiforme type) associated with thrombotic vasculopathy in a child during the COVID-19 pandemic. *J Eur Acad Dermatol Venereol* 2020; **34**. <https://doi.org/10.1111/jdv.16644>
- 11 Imbalzano E, Casciaro M, Quartuccio S *et al*. Association between urticaria and virus infections: a systematic review. *Allergy Asthma Proc* 2016; **37**: 18–22.
- 12 Sachdeva M, Gianotti R, Shah M *et al*. Cutaneous manifestations of COVID-19: report of three cases and a review of literature. *J Dermatol Sci* 2020; **98**: 75–81.
- 13 Fernandez-Nieto D, Ortega-Quijano D, Segurado-Miravalles G *et al*. Comment on: Cutaneous manifestations in COVID-19: a first perspective. Safety concerns of clinical images and skin biopsies. *J Eur Acad Dermatol Venereol* 2020; **34**: e252–4.
- 14 Rodriguez-Jimenez P, Chicharro P, De Argila D *et al*. Urticaria-like lesions in COVID-19 patients are not really urticaria – a case with clinicopathologic correlation. *J Eur Acad Dermatol Venereol* 2020; **42**: 564–70. <https://doi.org/10.1111/jdv.16618>
- 15 Gunawan C, Angela A, Widysanto A. Urticarial eruption in coronavirus disease 2019 (COVID-19) infection: a case report in Tangerang, Indonesia. *J Eur Acad Dermatol Venereol* 2020; **34**: e372–3.
- 16 Zhang JJ, Dong X, Cao YY *et al*. Clinical characteristics of 140 patients infected with SARS-CoV-2 in Wuhan, China. *Allergy* 2020; **75**: 1730–41.
- 17 Henry D, Ackerman M, Sancelme E *et al*. Urticarial eruption in COVID-19 infection. *J Eur Acad Dermatol Venereol* 2020; **34**: e244–5.
- 18 Aktas H, Hamidi AA. Urticaria in a patient with COVID-19: therapeutic and diagnostic difficulties. *Dermatol Ther* 2020; e13610. <https://doi.org/10.1111/dth.13610>
- 19 de Medeiros VLS, Silva LFT. Follow-up of skin lesions during the evolution of COVID-19: a case report. *Arch Dermatol Res* 2020; 1–4. <https://doi.org/10.1007/s00403-020-02091-0>
- 20 Naziroglu T, Sozen S, Ozkan P *et al*. A case of COVID-19 pneumonia presenting with acute urticaria. *Dermatol Ther* 2020; e13575. <https://doi.org/10.1111/dth.13575>
- 21 Damme C, Berlingin E, Saussez S, Accaputo O. Acute urticaria with pyrexia as the first manifestations of a COVID-19 infection. *J Eur Acad Dermatol Venereol* 2020; **334**: e300–1.
- 22 Estebanez A, Perez-Santiago L, Silva E *et al*. Cutaneous manifestations in COVID-19: a new contribution. *J Eur Acad Dermatol Venereol* 2020; **34**: e250–1.

- 23 Hedou M, Carsuzaa F, Chary E *et al.* Comment on "Cutaneous manifestations in COVID-19: a first perspective" by Recalcati S. *J Eur Acad Dermatol Venereol* 2020; **34**: e299–300.
- 24 Morey-Olive M, Espiau M, Mercadal-Hally M *et al.* Cutaneous manifestations in the current pandemic of coronavirus infection disease (COVID 2019). *An Pediatr (Engl Ed)* 2020; **92**: 374–5.
- 25 Young S, Fernandez AP. Skin manifestations of COVID-19. *Cleve Clin J Med* 2020. <https://doi.org/10.3949/ccjm.87a.ccc031>
- 26 de Masson A, Bouaziz JD, Sulimovic L *et al.* Chilblains are a common cutaneous finding during the COVID-19 pandemic: a retrospective nationwide study from France. *J Am Acad Dermatol* 2020; **83**: 667–70.
- 27 Gisoni P, Pflaserico S, Bordin C *et al.* Cutaneous manifestations of SARS-CoV-2 infection: a clinical update. *J Eur Acad Dermatol Venereol* 2020. <https://doi.org/10.1111/jdv.16774>
- 28 Marzano AV, Genovese G, Fabbrocini G *et al.* Varicella-like exanthema as a specific COVID-19-associated skin manifestation: multi-center case series of 22 patients. *J Am Acad Dermatol* 2020; **83**: 280–5.
- 29 De Giorgi V, Recalcati S, Jia Z *et al.* Cutaneous manifestations related to coronavirus disease 2019 (COVID-19): a prospective study from China and Italy. *J Am Acad Dermatol* 2020; **83**: 674–5.
- 30 Fernandez-Nieto D, Ortega-Quijano D, Jimenez-Cauhe J *et al.* Clinical and histological characterization of vesicular COVID-19 rashes: a prospective study in a tertiary care hospital. *Clin Exp Dermatol* 2020; **45**: 872–5. <https://doi.org/10.1111/ced.14277>
- 31 Marzano AV, Genovese G. Response to "Reply to 'Varicella-like exanthem as a specific COVID-19-associated skin manifestation: multicenter case series of 22 patients': To consider varicella-like exanthem associated with COVID-19, virus varicella zoster and virus herpes simplex must be ruled out". *J Am Acad Dermatol* 2020; **83**: e255–6.
- 32 Tang K, Wang Y, Zhang H *et al.* Cutaneous manifestations of the Coronavirus Disease 2019 (COVID-19): a brief review. *Dermatol Ther* 2020; e13528. <https://doi.org/10.1111/dth.13528>
- 33 Gianotti R, Veraldi S, Recalcati S *et al.* Cutaneous clinico-pathological findings in three COVID-19-positive patients observed in the metropolitan area of Milan, Italy. *Acta Derm Venereol* 2020; **100**: adv00124.
- 34 Genovese G, Colonna C, Marzano AV. Varicella-like exanthem associated with COVID-19 in an 8-year-old girl: a diagnostic clue? *Pediatr Dermatol* 2020; **37**: 435–6.
- 35 Piccolo V, Neri I, Filippeschi C *et al.* Chilblain-like lesions during COVID-19 epidemic: a preliminary study on 63 patients. *J Eur Acad Dermatol Venereol* 2020; **34**: e29–3.
- 36 Wollina U, Karadağ AS, Rowland-Payne C *et al.* Cutaneous signs in COVID-19 patients: a review. *Dermatol Ther* 2020; e13549.
- 37 Mahé A, Birckel A, Merklen C *et al.* Histology of skin lesions establishes that the vesicular rash associated with COVID-19 is not 'varicella-like'. *J Eur Acad Dermatol Venereol* 2020; **34**: e559–61. <https://doi.org/10.1111/jdv.16706>
- 38 Mahe A, Birckel E, Krieger S *et al.* A distinctive skin rash associated with coronavirus disease 2019. *J Eur Acad Dermatol Venereol* 2020; **34**: e246–7.
- 39 Schnabel A, Hedrich CM. Childhood vasculitis. *Front Pediatr* 2018; **6**: 421.
- 40 Makino N, Nakamura Y, Yashiro M *et al.* Nationwide epidemiologic survey of Kawasaki disease in Japan, 2015–16. *Pediatr Int Off J Jpn Pediatr Soc* 2019; **61**: 397–403.
- 41 Esper F, Shapiro ED, Weibel C *et al.* Association between a novel human coronavirus and Kawasaki disease. *J Infect Dis* 2005; **191**: 499–502.
- 42 Esper F, Weibel C, Ferguson D *et al.* Evidence of a novel human coronavirus that is associated with respiratory tract disease in infants and young children. *J Infect Dis* 2005; **191**: 492–8.
- 43 Chang L-Y, Lu C-Y, Shao P-L *et al.* Viral infections associated with Kawasaki disease. *J Formos Med Assoc Taiwan Yi Zhi* 2014; **113**: 148–54.
- 44 Dong Y, Mo X, Hu Y *et al.* Epidemiology of COVID-19 among children in China. *Pediatrics* 2020; **145**: e20200702.
- 45 Riphagen S, Gomez X, Gonzalez-Martinez C *et al.* Hyperinflammatory shock in children during COVID-19 pandemic. *Lancet (Lond) Engl* 2020; **39**: 1607–8.
- 46 Cabrero-Hernández M, García-Salido A, Leoz-Gordillo I *et al.* Severe SARS-CoV-2 infection in children with suspected acute abdomen: a case series from a tertiary hospital in Spain. *Pediatr Infect Dis J* 2020; **39**: e195–8.
- 47 Verdoni L, Mazza A, Gervasoni A *et al.* An outbreak of severe Kawasaki-like disease at the Italian epicentre of the SARS-CoV-2 epidemic: an observational cohort study. *Lancet (Lond) Engl* 2020; **395**: 1771–8.
- 48 Toubiana J, Poirault C, Corsia A *et al.* Kawasaki-like multisystem inflammatory syndrome in children during the covid-19 pandemic in Paris, France: prospective observational study. *BMJ* 2020; **369**: m2094.
- 49 Trouillet-Assant S, Viel S, Gaymard A *et al.* Type I IFN immunoprofiling in COVID-19 patients. *J Allergy Clin Immunol* 2020; **146**: 206–8.e2.
- 50 ECDC. Paediatric inflammatory multisystem syndrome and SARSCoV- 2 infection in children, 2020. Available at: <https://www.ecdc.europa.eu/sites/default/files/documents/covid-19-riskassessment-paediatricinflammatory-multisystem-syndrome-15-May-2020.pdf> (accessed 15 May 2020).
- 51 CDC. Multisystem inflammatory syndrome in children (MIS-C) associated with coronavirus disease 2019 (COVID-19), 2020. Available at: <https://emergency.cdc.gov/han/2020/han00432.asp> (accessed 14 May 2020).

- 52 Jones VG, Mills M, Suarez D *et al.* COVID-19 and Kawasaki disease: novel virus and novel case. *Hosp Pediatr* 2020; **10**: 537–40.
- 53 Licciardi F, Pruccoli G, Denina M *et al.* SARS-CoV-2-Induced Kawasaki-like hyperinflammatory syndrome: a novel COVID phenotype in children. *Pediatrics* 2020; **146**: e20201711.
- 54 Yancy CW. COVID-19 and African Americans. *JAMA* 2020; **323**: 1891–2.
- 55 Giudicessi JR, Roden DM, Wild A, Ackerman MJ. Genetic susceptibility for COVID-19-associated sudden cardiac death in African Americans. *Heart Rhythm* 2020; **17**: 1487–92.
- 56 Oualha M, Bendavid M, Berteloot L *et al.* Severe and fatal forms of COVID-19 in children. *Arch Pediatr* 2020; **27**: 235–8.
- 57 McCrindle BW, Rowley AH, Newburger JW *et al.* Diagnosis, treatment, and long-term management of Kawasaki disease: a scientific statement for health professionals from the American Heart Association. *Circulation* 2017; **135**: e927–99.
- 58 Grimaud M, Starck J, Levy M *et al.* Acute myocarditis and multisystem inflammatory emerging disease following SARS-CoV-2 infection in critically ill children. *Ann Intensive Care* 2020; **10**: 69.
- 59 Li Y, Zheng Q, Zou L *et al.* Kawasaki disease shock syndrome: clinical characteristics and possible use of IL-6, IL-10 and IFN- γ as biomarkers for early recognition. *Pediatr Rheumatol Online J* 2019; **17**: 1.
- 60 Mehta P, McAuley DF, Brown M *et al.* COVID-19: consider cytokine storm syndromes and immunosuppression. *Lancet (Lond) Engl* 2020; **395**: 1033–4.
- 61 Huang C, Wang Y, Li X *et al.* Clinical features of patients infected with 2019 novel coronavirus in Wuhan, China. *Lancet* 2020; **395**: 497–506.
- 62 Turnier JL, Anderson MS, Heizer HR *et al.* Concurrent respiratory viruses and Kawasaki disease. *Pediatrics* 2015; **136**: 609–14.
- 63 Shirato K, Imada Y, Kawase M *et al.* Possible involvement of infection with human coronavirus 229E, but not NL63, in Kawasaki disease. *J Med Virol* 2014; **86**: 2146–53.
- 64 Ebihara T, Endo R, Ma X *et al.* Lack of association between New Haven coronavirus and Kawasaki disease. *J Infect Dis* 2005; **19**: 351–2.
- 65 Schroeder AR, Wilson KM, Ralston SL. COVID-19 and Kawasaki disease: finding the signal in the noise. *Hosp Pediatr* 2020; **10**: e1–3. <https://doi.org/10.1542/hpeds.2020-000356>
- 66 Kanegaye JT, Wilder MS, Molkara D *et al.* Recognition of a Kawasaki disease shock syndrome. *Pediatrics* 2009; **123**: 783–9.
- 67 Zulfqar AA, Lorenzo-Villalba N, Hassler P, Andrès E. Immune thrombocytopenic purpura in a patient with Covid-19. *N Engl J Med* 2020; **382**: e43.
- 68 Joob B, Wiwanitkit V. COVID-19 can present with a rash and be mistaken for Dengue. *J Am Acad Dermatol* 2020; **82**: e17.
- 69 Jimenez-Cauhe J, Ortega-Quijano D, Prieto-Barrios M *et al.* Reply to "COVID-19 can present with a rash and be mistaken for Dengue": Petechial rash in a patient with COVID-19 infection. *J Am Acad Dermatol* 2020; **8**: e141–2.
- 70 Zhang Y, Cao W, Xiao M *et al.* Clinical and coagulation characteristics of 7 patients with critical COVID-2019 pneumonia and acro-ischemia. *Zhonghua Xue Ye Xue Za Zhi* 2020; **41**: E006.
- 71 Bouaziz JD, Duong T, Jachiet M *et al.* Vascular skin symptoms in COVID-19: a French observational study. *J Eur Acad Dermatol Venereol* 2020; **34**. <https://doi.org/10.1111/jdv.16544>.
- 72 Olisova OY, Anpilogova EM, Shnakhova LM. Cutaneous manifestations in COVID-19: a skin rash in a child. *Dermatol Ther* 2020; e13712. <https://doi.org/10.1111/dth.13712>
- 73 Kamali Aghdam M, Jafari N, Eftekhari K. Novel coronavirus in a 15-day-old neonate with clinical signs of sepsis, a case report. *Infect Dis (Lond)* 2020; **183**: 591–3.
- 74 Kang JH. Febrile illness with skin rashes. *Infect Chemother* 2015; **47**: 155–66.
- 75 Llamas-Velasco M, Muñoz-Hernández P, Lázaro-González J *et al.* Thrombotic occlusive vasculopathy in skin biopsy from a livedoid lesion of a COVID-19 patient. *Br J Dermatol* 2020; **183**: 591–3. <https://doi.org/10.1111/bjd.19222>
- 76 Diaz-Guimaraens B, Dominguez-Santas M, Suarez-Valle A *et al.* Petechial skin rash associated with severe acute respiratory syndrome coronavirus 2 infection. *JAMA Dermatol* 2020; **156**: 820. <https://doi.org/10.1001/jamadermatol.2020.1741>
- 77 Recalcati S. Cutaneous manifestations in COVID-19: a first perspective. *J Eur Acad Dermatol Venereol* 2020; **34**: e212–13.
- 78 Herrero-Moyano M, Capusan TM, Andreu-Barasoain M *et al.* A clinicopathological study of 8 patients with COVID-19 pneumonia and a late-onset exanthema. *J Eur Acad Dermatol Venereol* 2020. <https://doi.org/10.1111/jd.v.16631>
- 79 Reymundo A, Fernández-Bernáldez A, Reolid A *et al.* Clinical and histological characterization of late appearance maculopapular eruptions in association with the coronavirus disease 2019. A case series of seven patients. *J Eur Acad Dermatol Venereol* 2020; <https://doi.org/10.1111/jdv.16707>
- 80 Delaleu J, Deniau B, Battistella M *et al.* Acute generalized exanthematous pustulosis induced by hydroxychloroquine prescribed for COVID-19. *J Allergy Clin Immunol Pract* 2020; **8**: 2777–9.e1. <https://doi.org/10.1016/j.jaip.2020.05.046>
- 81 Ehsani AH, Nasimi M, Bigdelo Z. Pityriasis rosea as a cutaneous manifestation of COVID-19 infection. *J Eur Acad Dermatol Venereol* 2020; **34**. <https://doi.org/10.1111/jdv.16579>

- 82 Dursun R, Temiz SA. The clinics of HHV-6 infection in COVID-19 pandemic: pityriasis rosea and Kawasaki disease. *Dermatol Ther* 2020; e13730. <https://doi.org/10.1111/dth.13730>
- 83 Nuno-Gonzalez A, Martin-Carrillo P, Magaletsky K, et al. Prevalence of mucocutaneous manifestations, oral and palmoplantar findings in 666 patients with COVID-19 in a field hospital in Spain. *Br J Dermatol*. 2020;<https://www.ncbi.nlm.nih.gov/pmc/articles/PMC7537506/pdf/BJD-9999-na.pdf>
- 84 Tartari F, Spadotto A, Zengarini C et al. Herpes zoster in COVID-19-positive patients. *Int J Dermatol* 2020; **59**: 1028–9.
- 85 Llamas-Velasco M, Rodríguez-Jiménez P, Chicharro P et al. Reply to "Varicella-like exanthem as a specific COVID-19-associated skin manifestation: multicenter case series of 22 patients": To consider varicella-like exanthem associated with COVID-19, virus varicella zoster and virus herpes simplex must be ruled out. *J Am Acad Dermatol* 2020; **83**: e253–4.

CPD questions

Learning objective

To gain up-to-date knowledge about rarer manifestations of COVID-19-related skin diseases.

Question 1

Which of the following statements about erythema multiforme in the setting of COVID-19 is true?

- (a) Lesions are mostly located on the face and trunk.
- (b) Lesions sometimes appear in association with chilblains.
- (c) A positive PCR result to SARS-CoV-2 has been reported in the majority of these cases.
- (d) All patients reported to date had systemic symptoms of COVID-19.
- (e) It has a severe and prolonged course.

Question 2

Which of the following is the most common skin manifestation in patients with COVID-19?

- (a) Chilblains.
- (b) Urticaria.
- (c) Vesicular exanthem.
- (d) Maculopapular eruption.
- (e) Purpuric exanthem.

Question 3

Which of the following skin signs is not characteristic of paediatric inflammatory multisystem syndrome?

- (a) Nonexudative conjunctivitis.
- (b) Erythematous rash.

- (c) Splinter haemorrhage of the fingernails.
- (d) Perineal desquamation.
- (e) Hand erythema and induration.

Question 4

Which of the following signs is more frequent in paediatric inflammatory multisystem syndrome than in Kawasaki disease?

- (a) Prominent gastrointestinal symptoms.
- (b) Myocarditis.
- (c) Shock.
- (d) All of the above.
- (e) None of the above.

Question 5

Which of the following skin manifestations has not been reported to be linked to COVID-19?

- (a) Lichen planus.
- (b) Livedoid eruptions.
- (c) Pityriasis rosea.
- (d) Macroglossia.
- (e) Retiform purpura.

Instructions for answering questions

This learning activity is freely available online at <http://www.wileyhealthlearning.com/ced>

Users are encouraged to

- Read the article in print or online, paying particular attention to the learning points and any author conflict of interest disclosures.
- Reflect on the article.
- Register or login online at <http://www.wileyhealthlearning.com/ced> and answer the CPD questions.

- Complete the required evaluation component of the activity.

Once the test is passed, you will receive a certificate and the learning activity can be added to your RCP CPD diary as a self-certified entry.

This activity will be available for CPD credit for 2 years following its publication date. At that time, it will be reviewed and potentially updated and extended for an additional period.